Dermatopathology Slide Review Part 42

Paul K. Shitabata, M.D.
Dermatopathology Institute

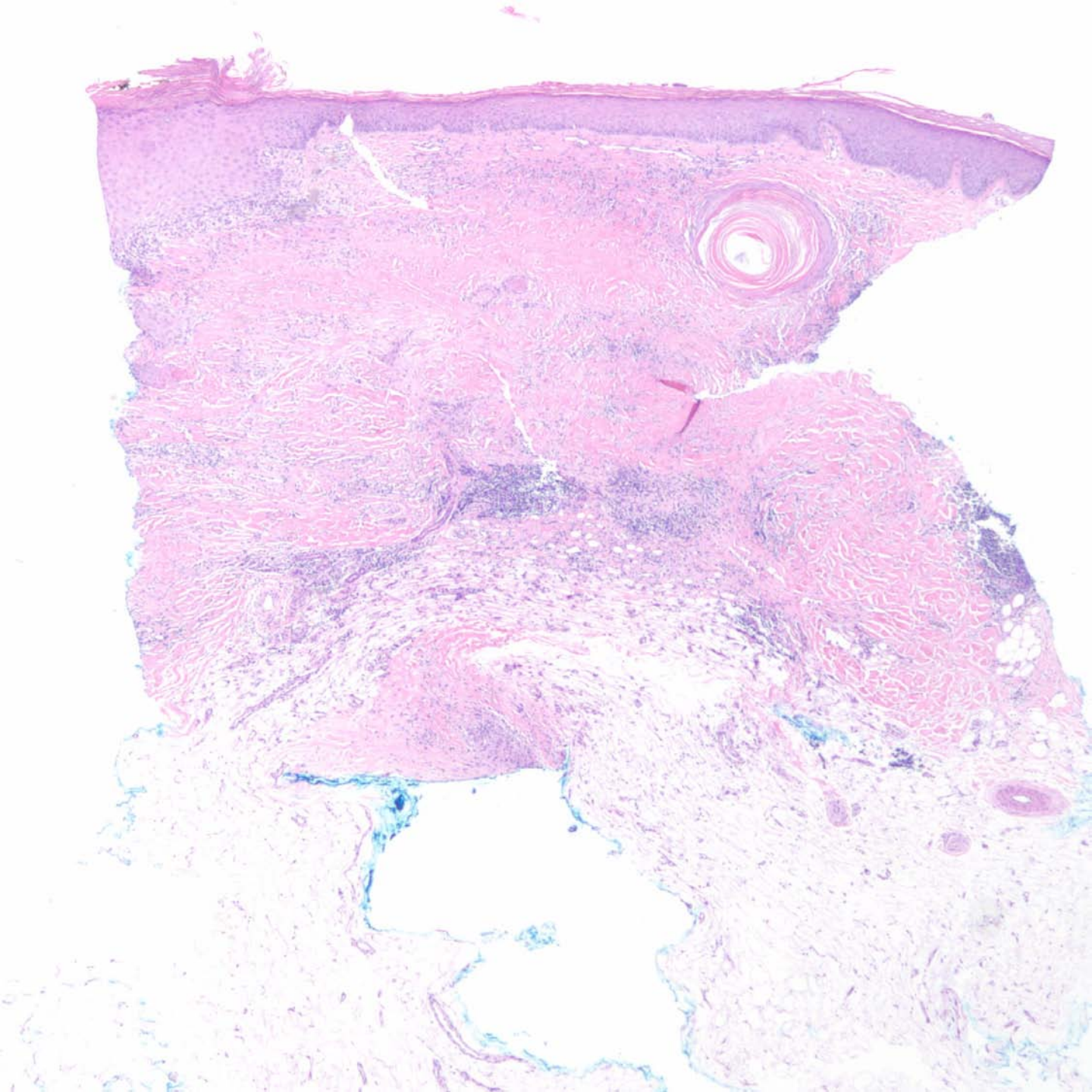

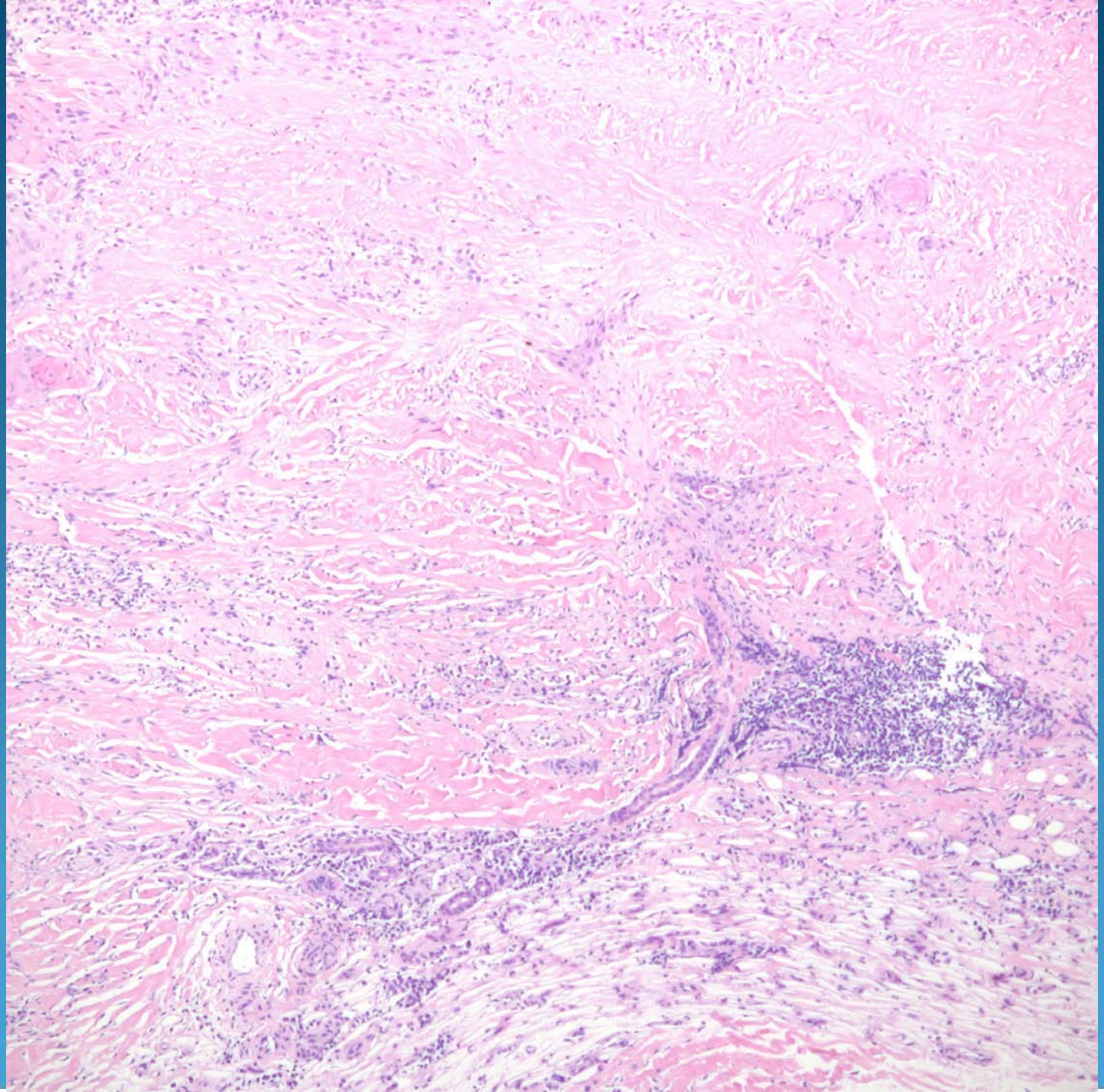

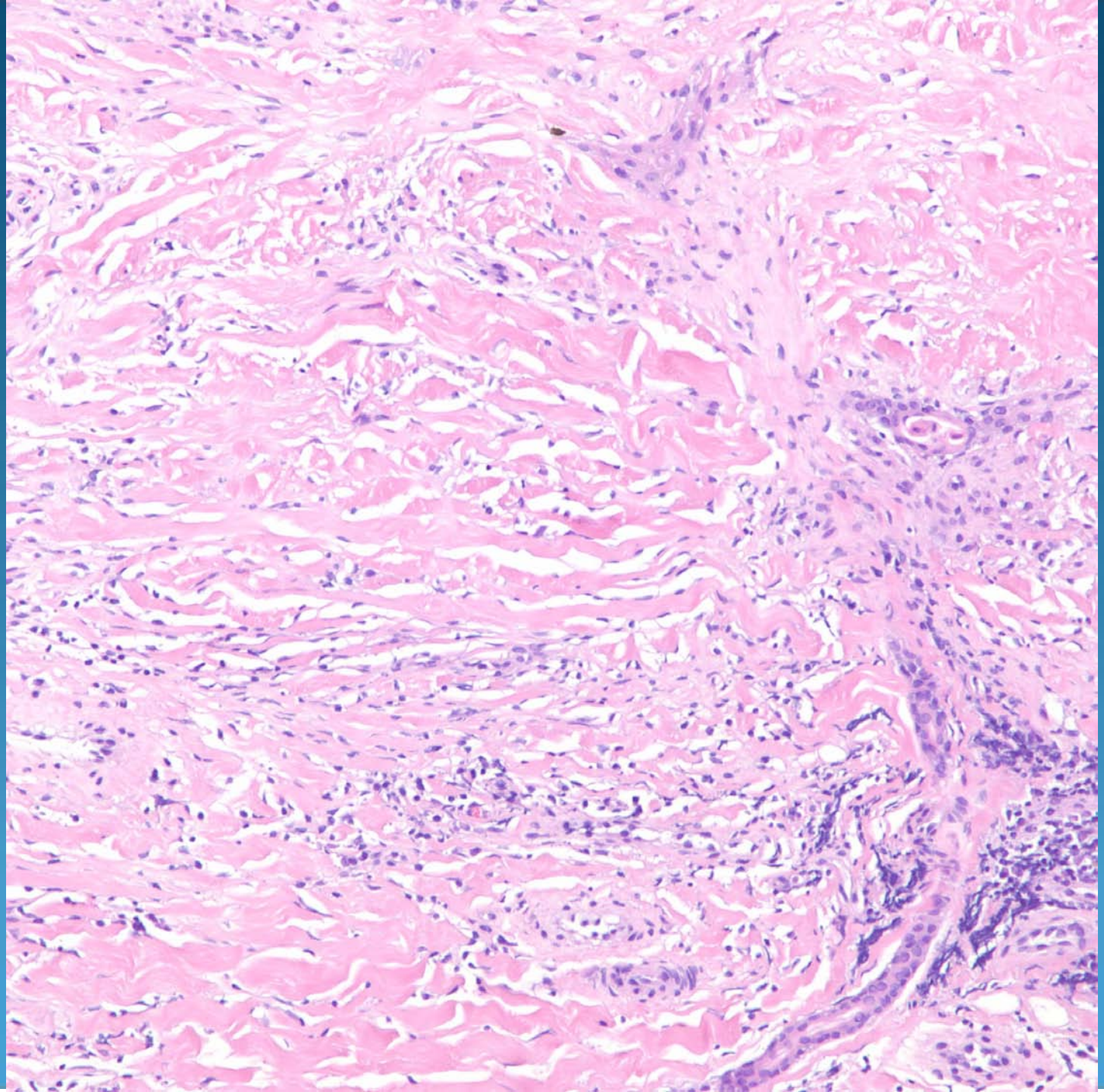

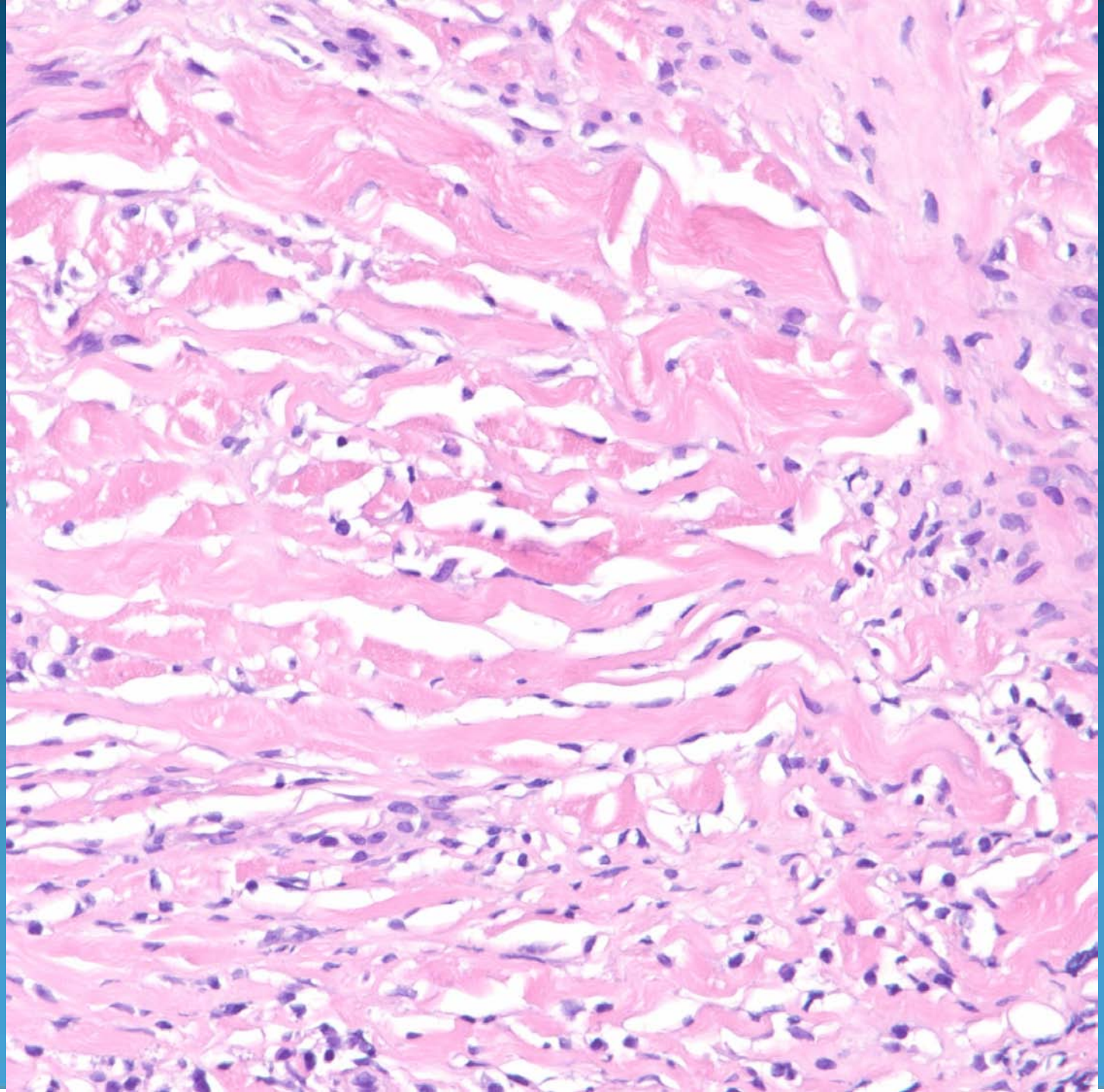

Necrobiosis lipoidica

Pearls

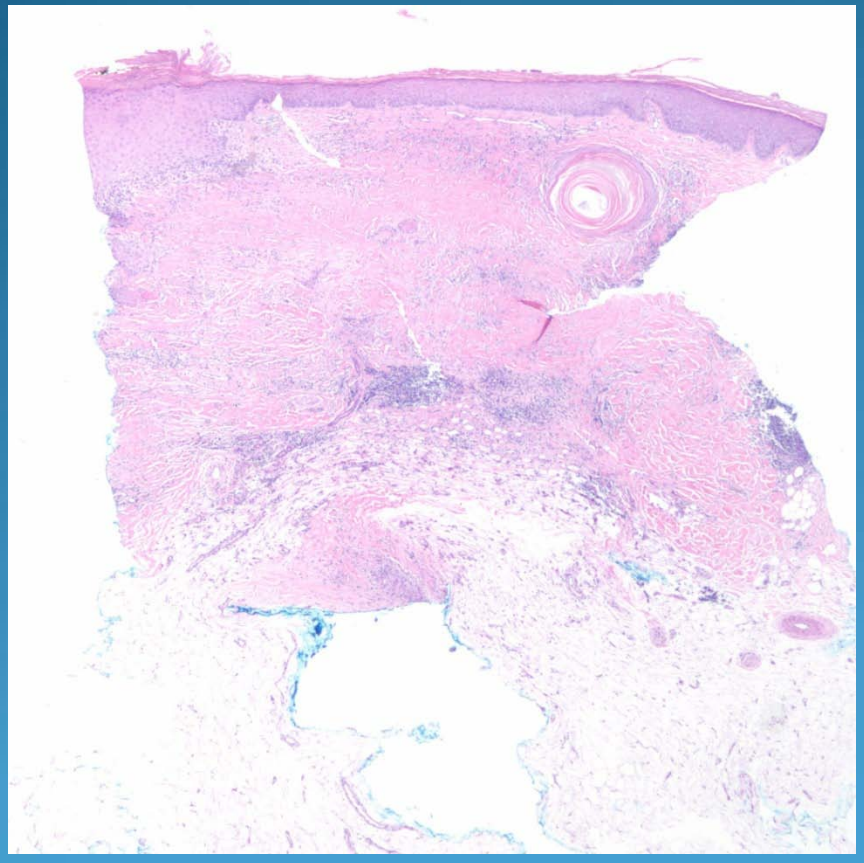

- Palisading necrobiosis in stair-case like extension to deep reticular dermis
- Mixed chronic inflammatory infiltrate with plasma cells
- DDX: Granuloma annulare

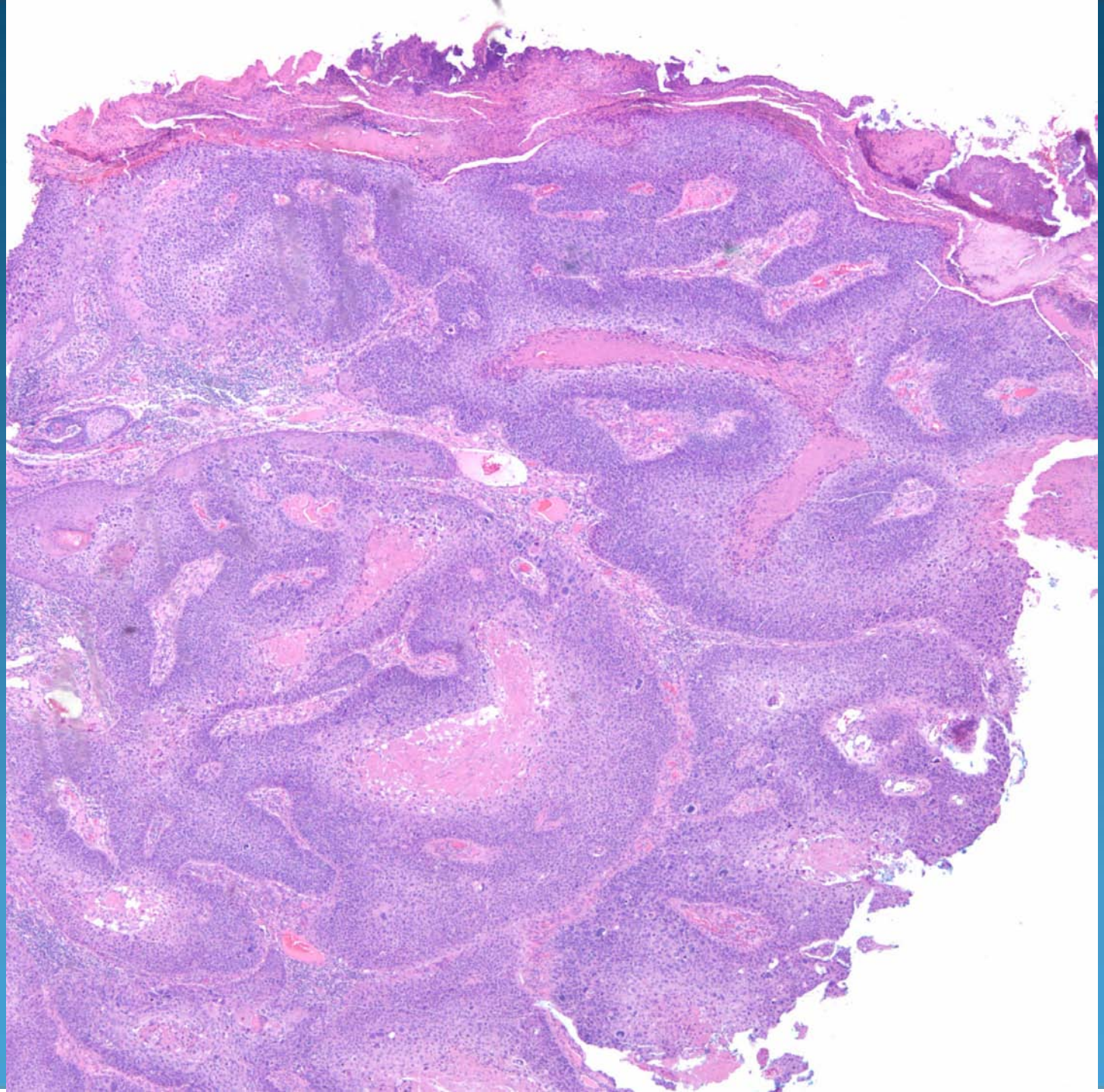

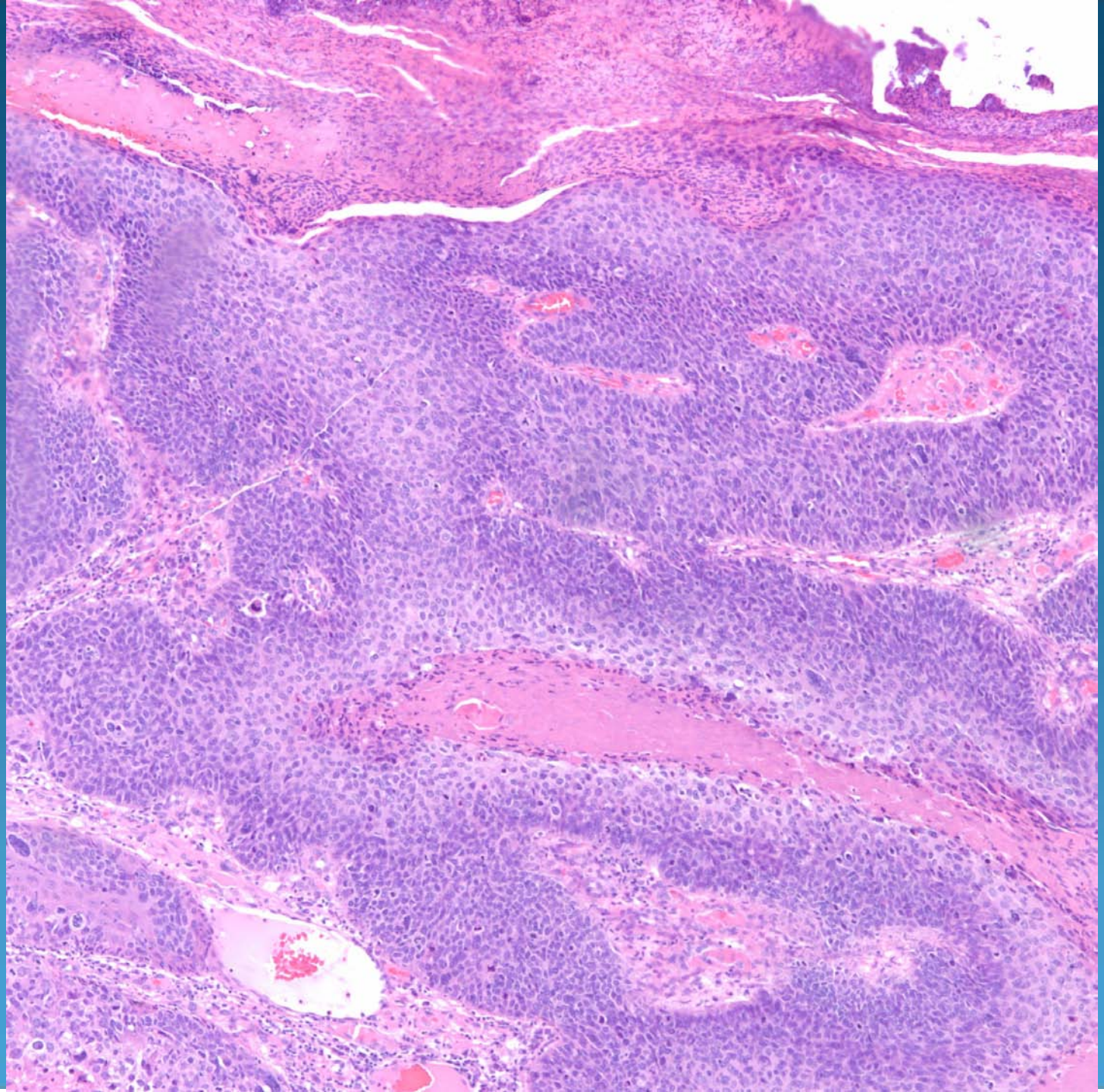

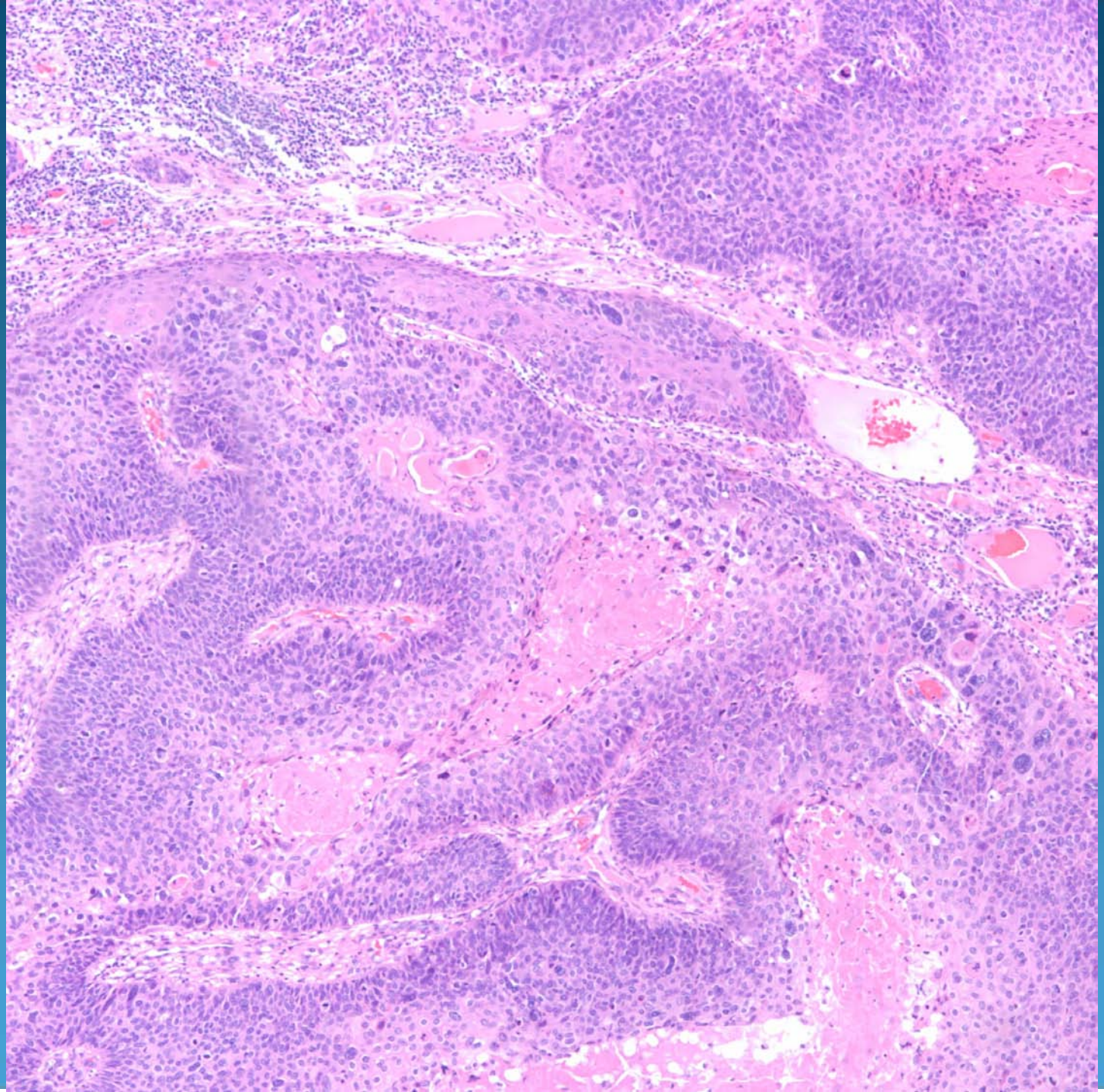

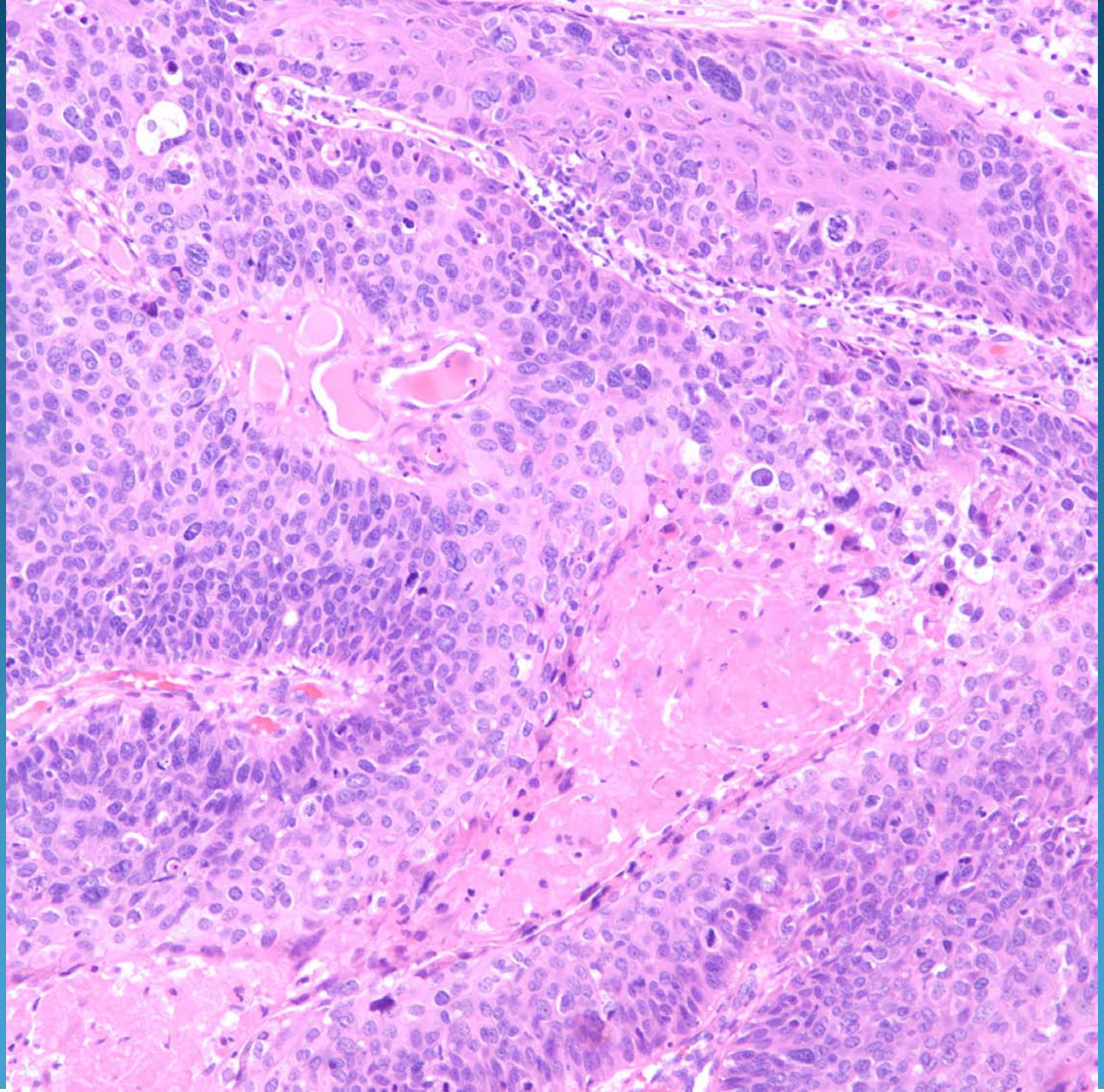

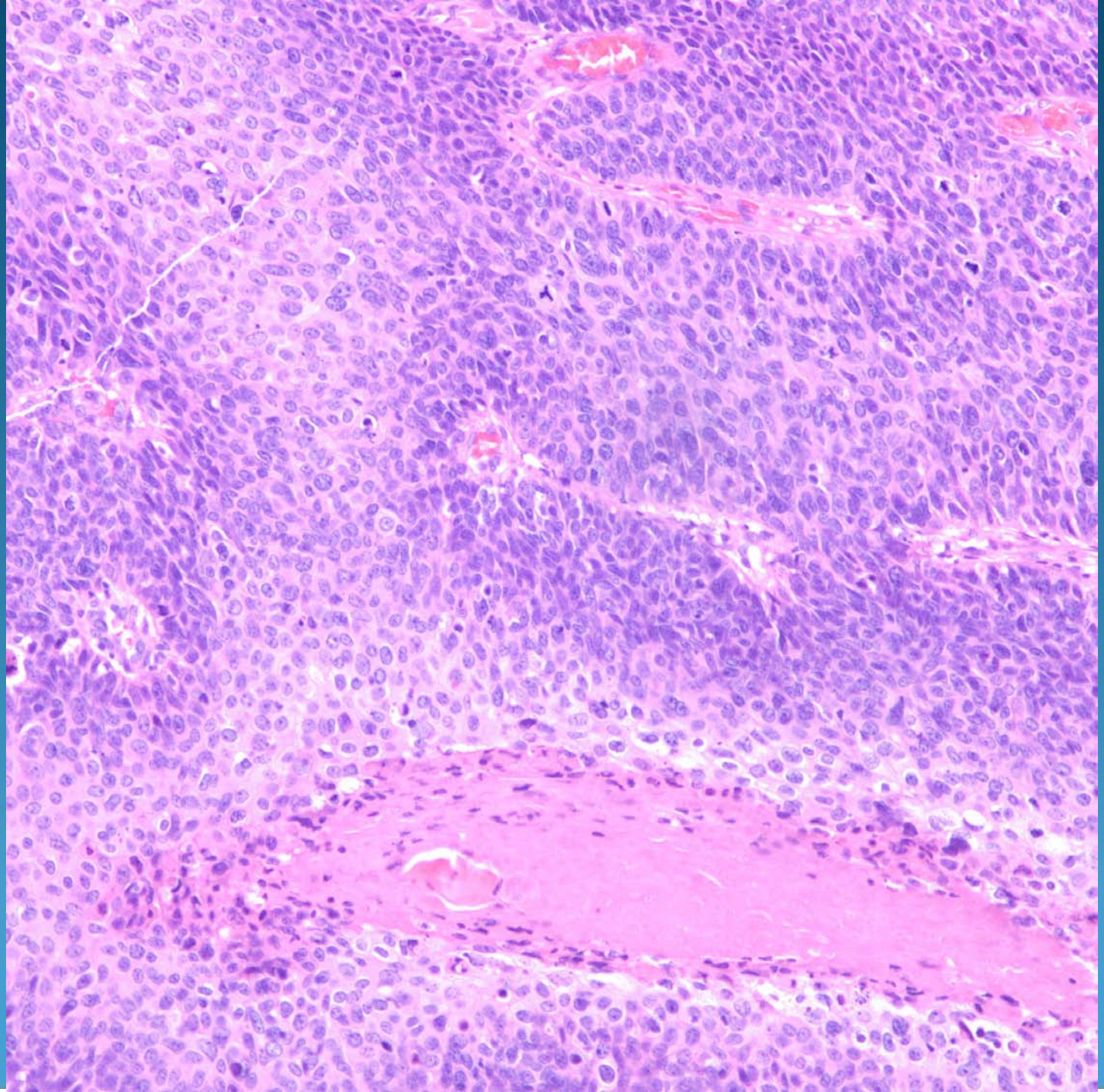

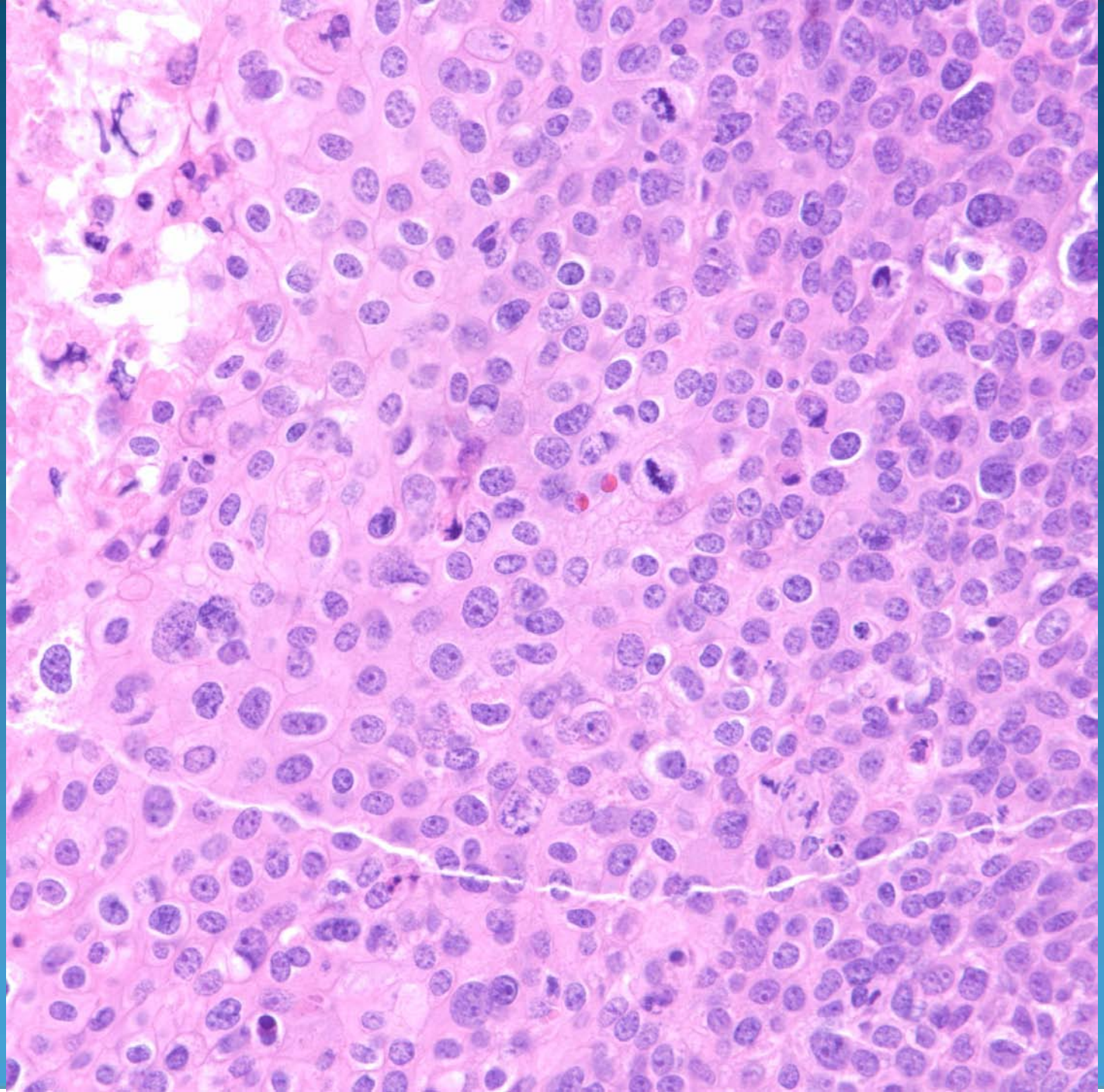

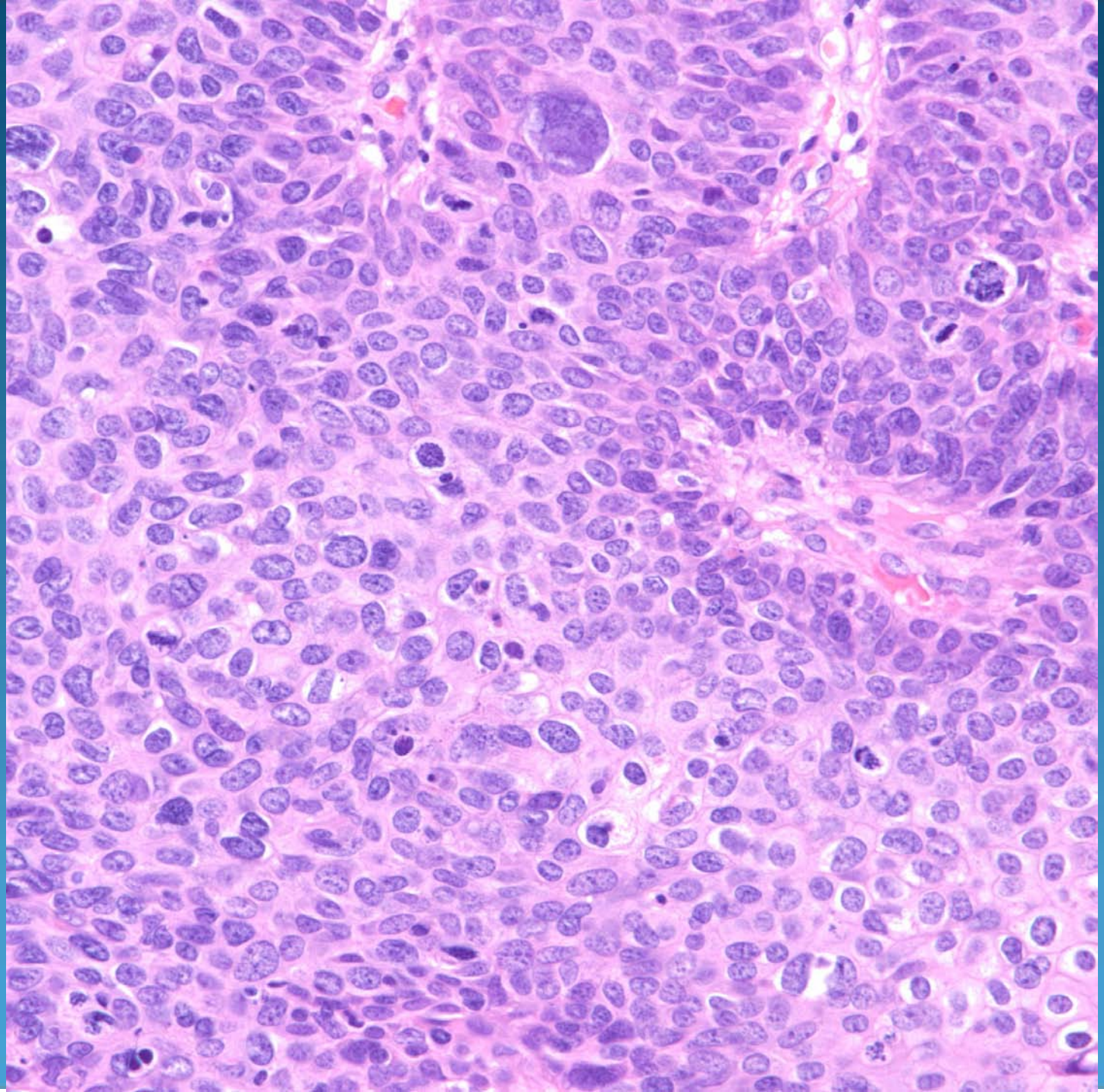

Invasive Bowenoid Squamous Cell Carcinoma

Pearls

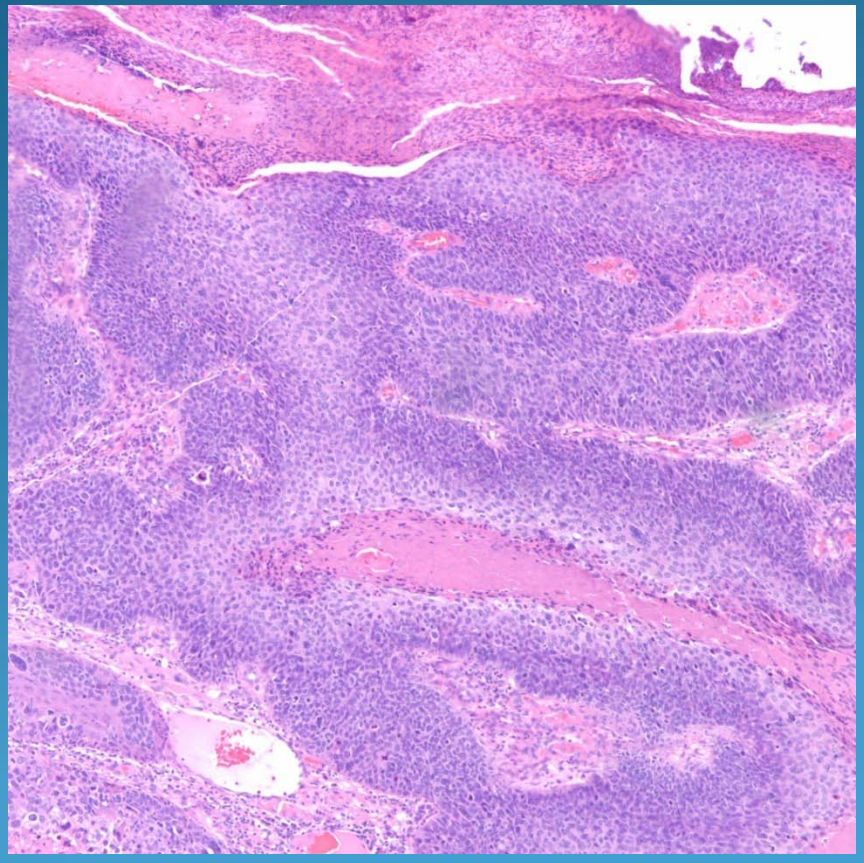

- Epidermis replaced by full thickness atypical squamous cells (Bowen's disease)
- Epidermis in continuity with invasive nests
- High grade pleomorphic nuclei

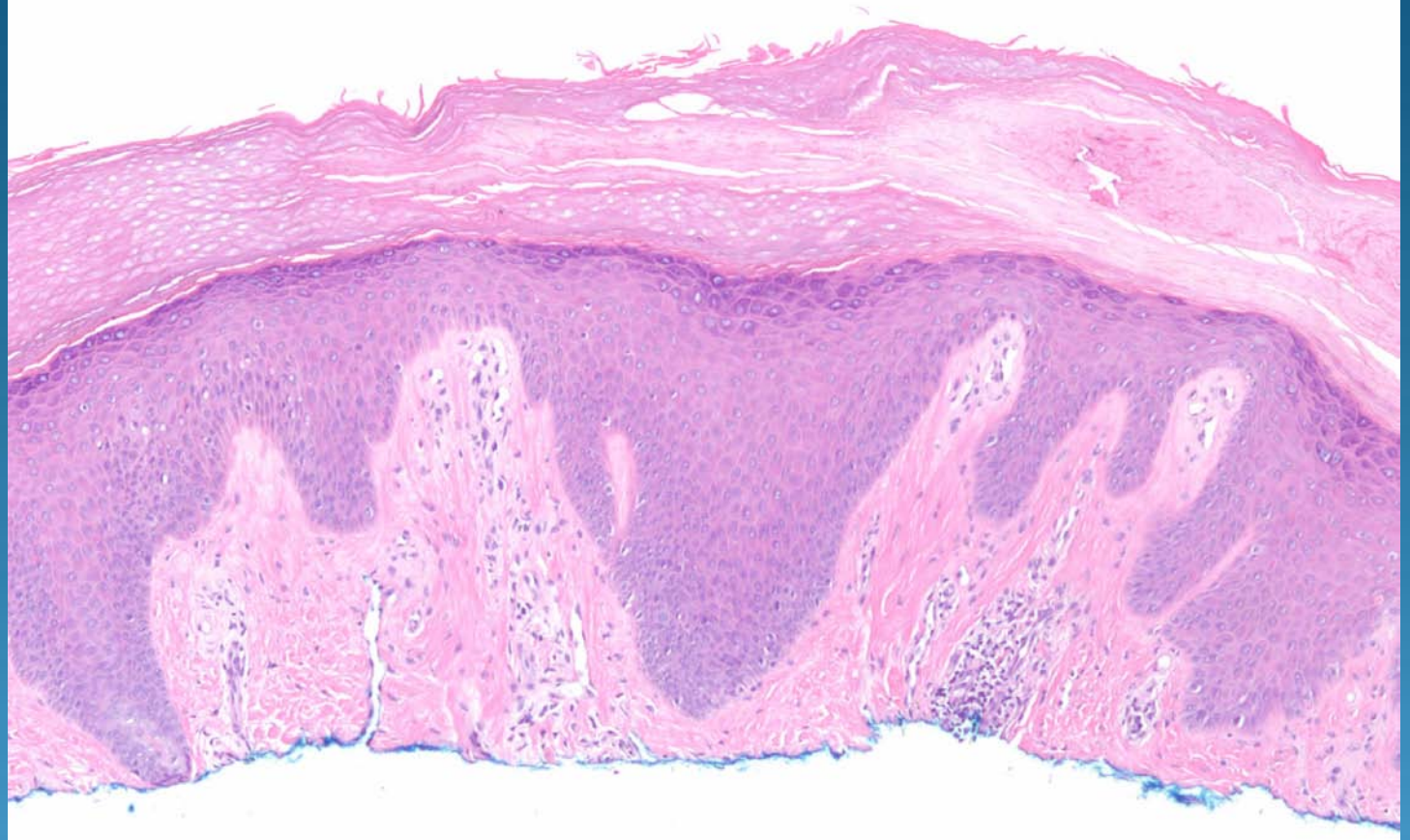

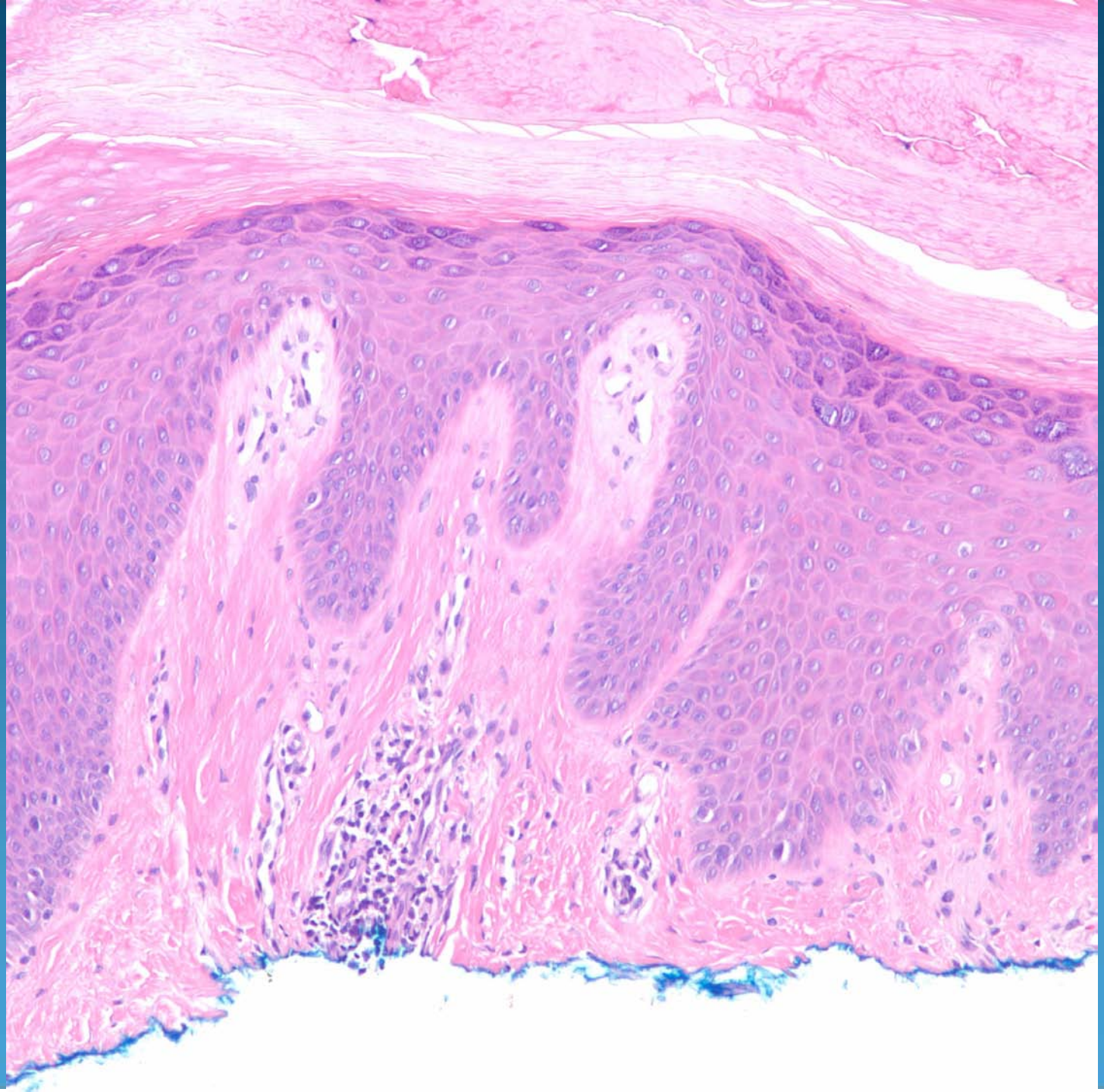

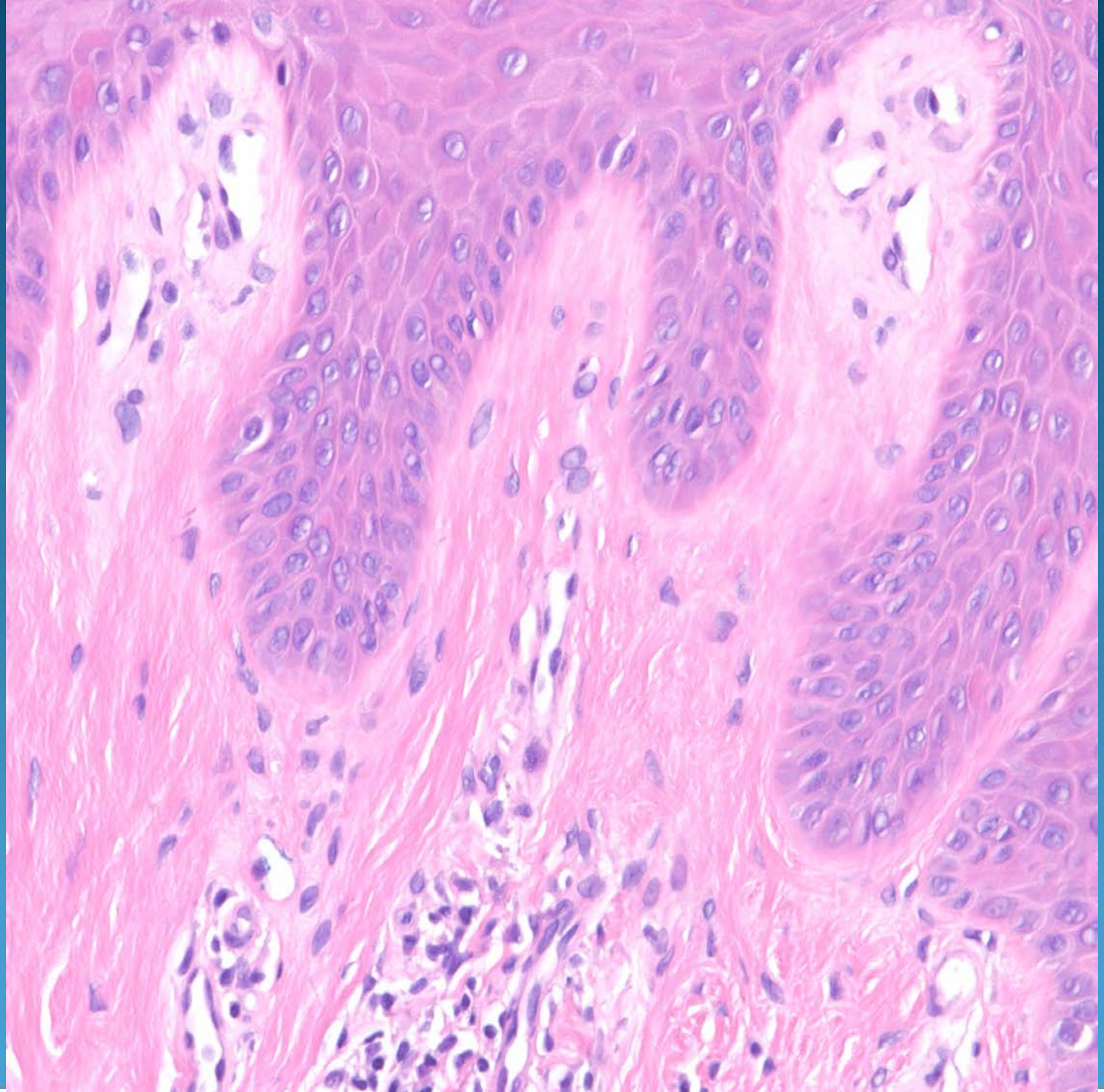

Lichen Simplex Chronicus

Pearls

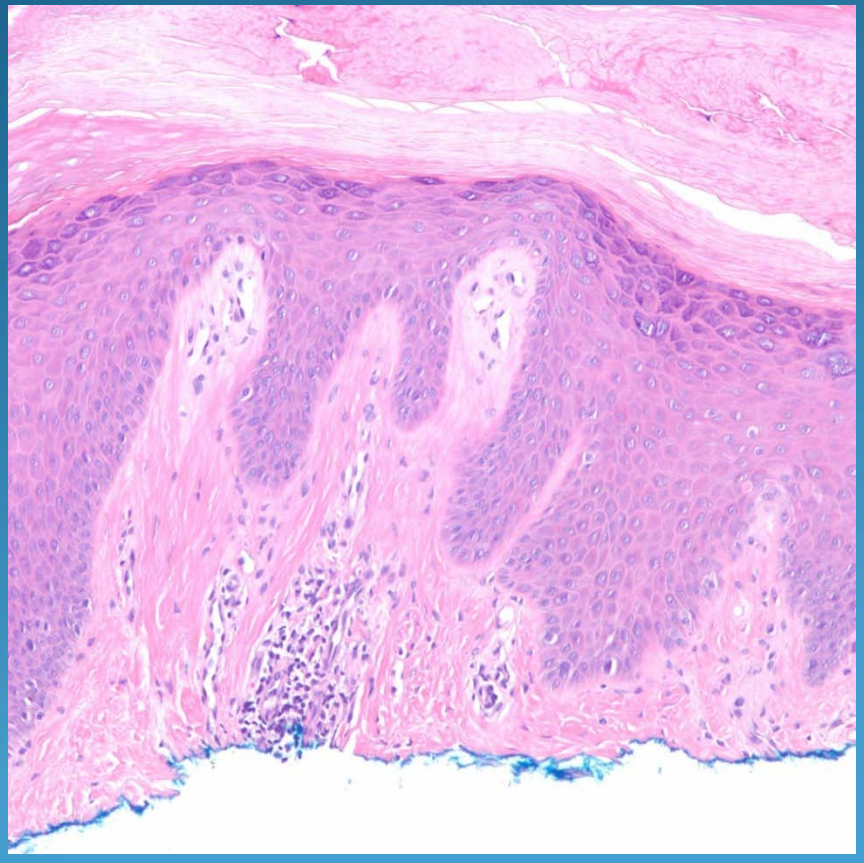

- Variable epidermal hyperplasia with hyperkeratosis-may have stratum lucidum
- Dermal papillary fibrosis
- Continuum with prurigo nodularis
- Keratinocytes with no viral cytopathic changes or atypia

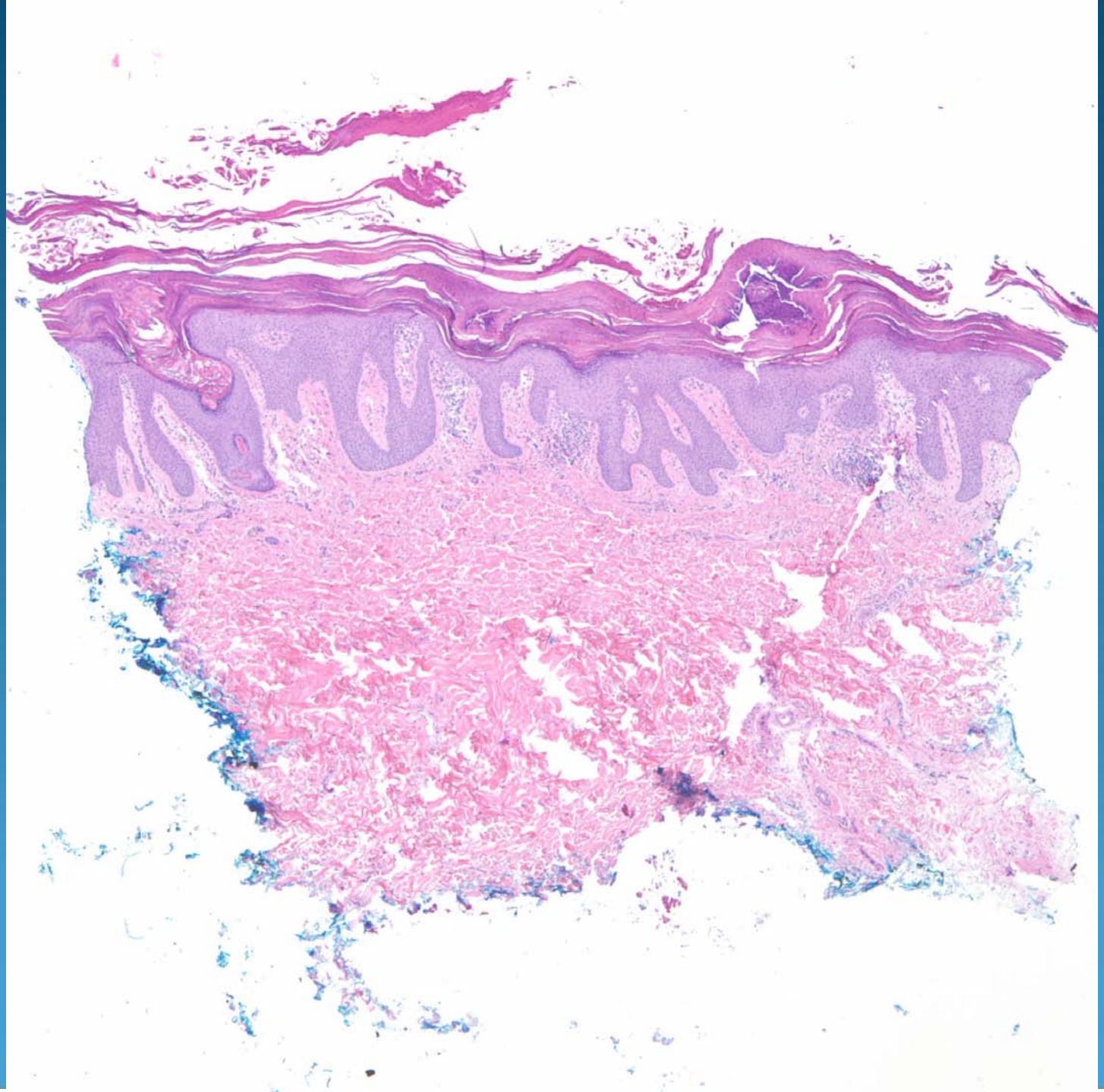

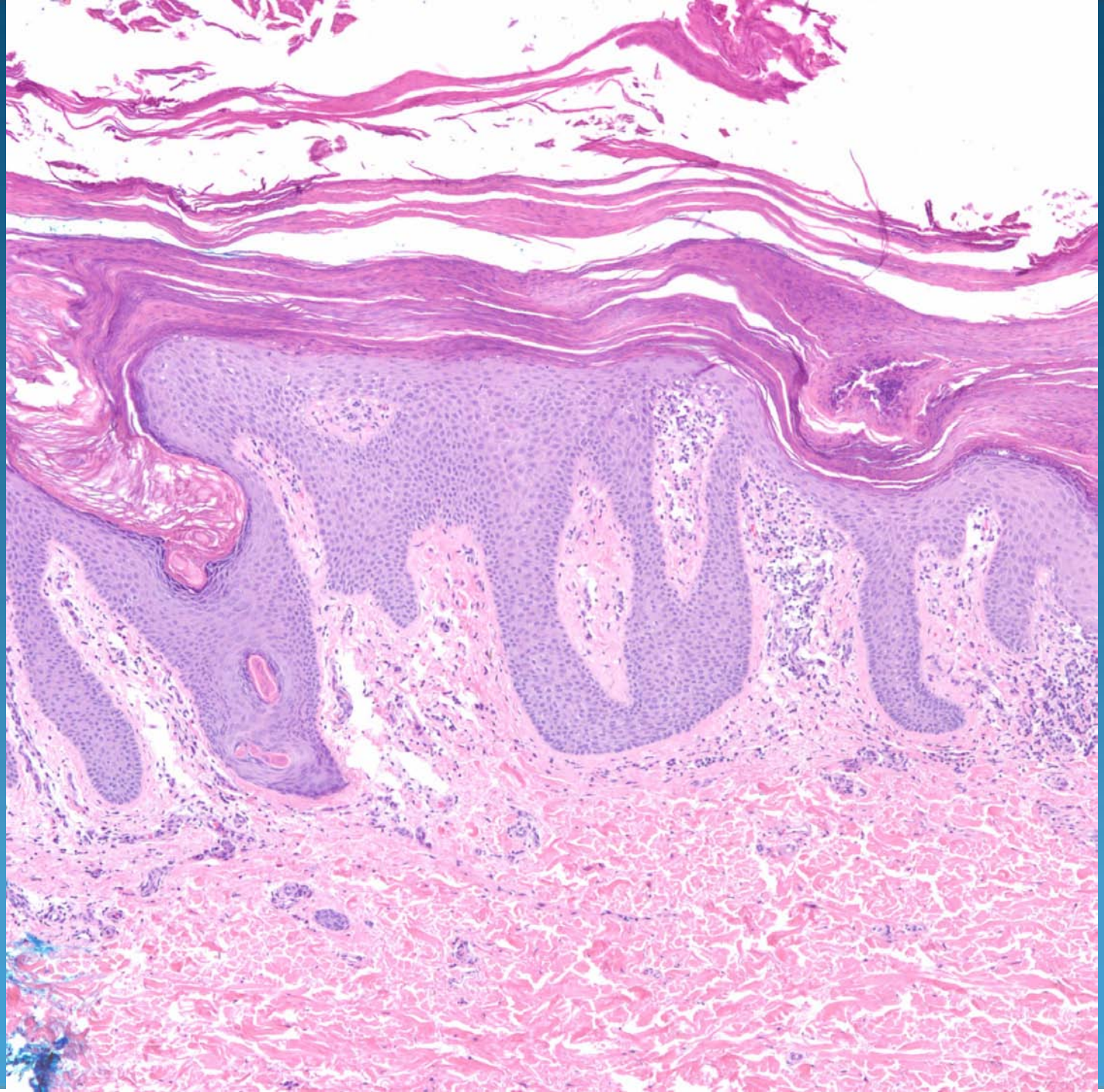

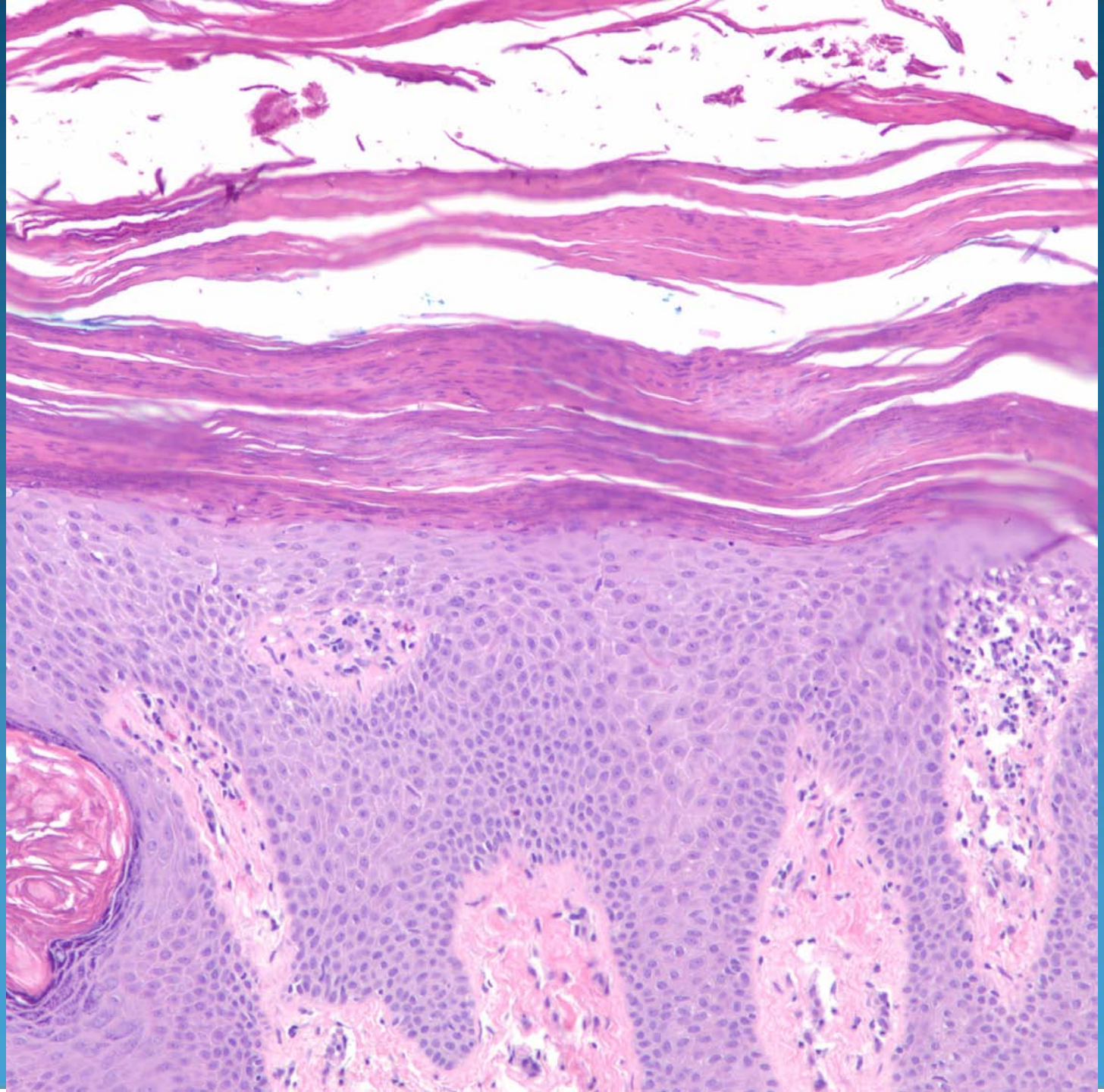

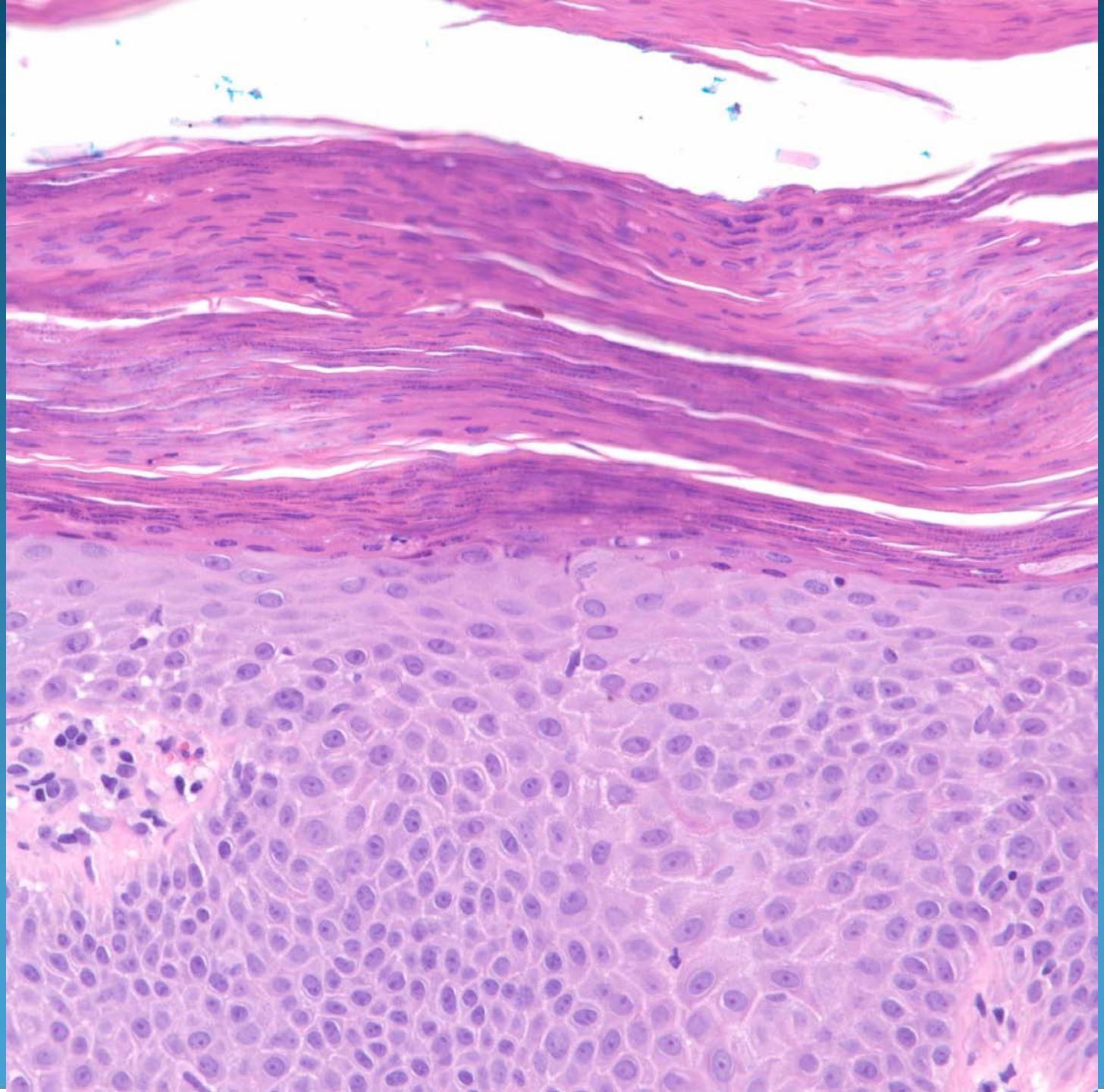

Axillary Granular Parakeratosis

Pearls

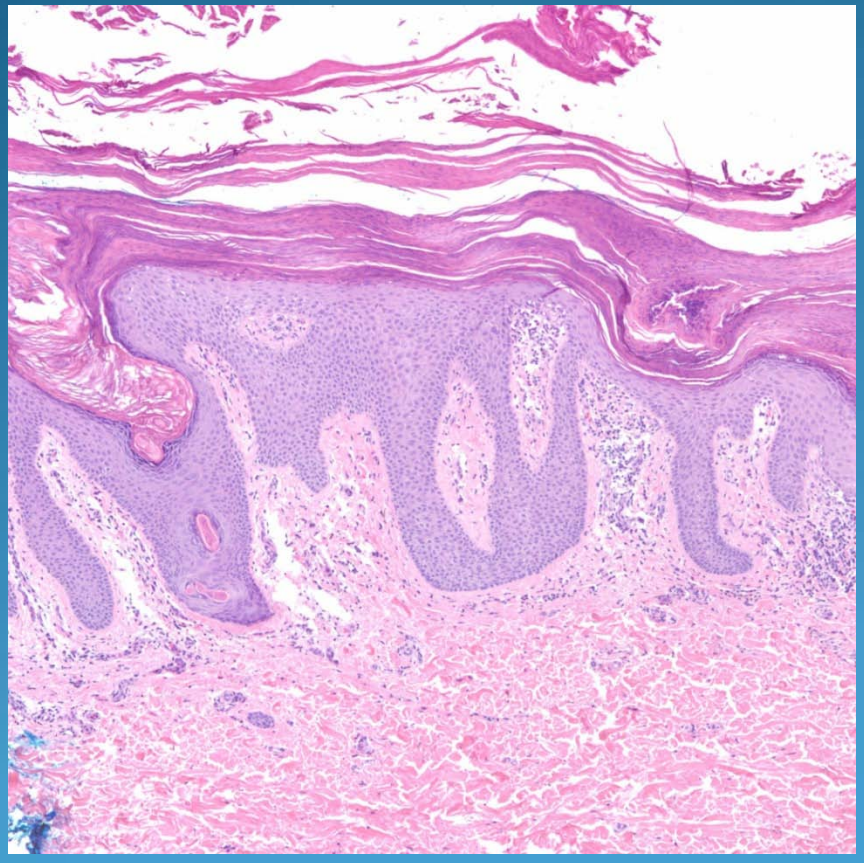

- Pronounced hyper- and parakeratotic scale without hypergranulosis
- Psoriasiform epidermal changes
- Clinical-pathological correlation
- DDX: Psoriasis, Pityriasis rubra pilaris

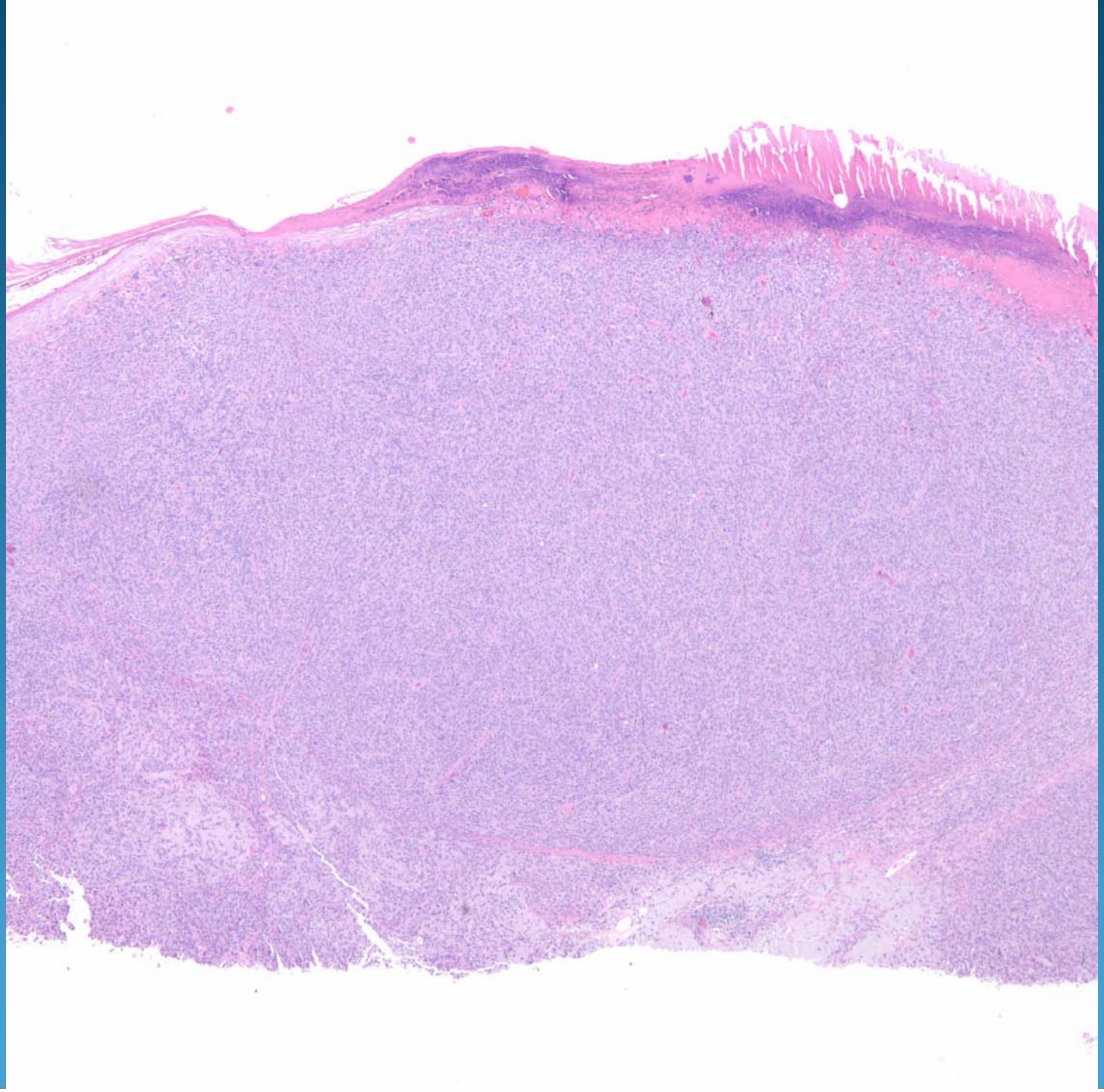

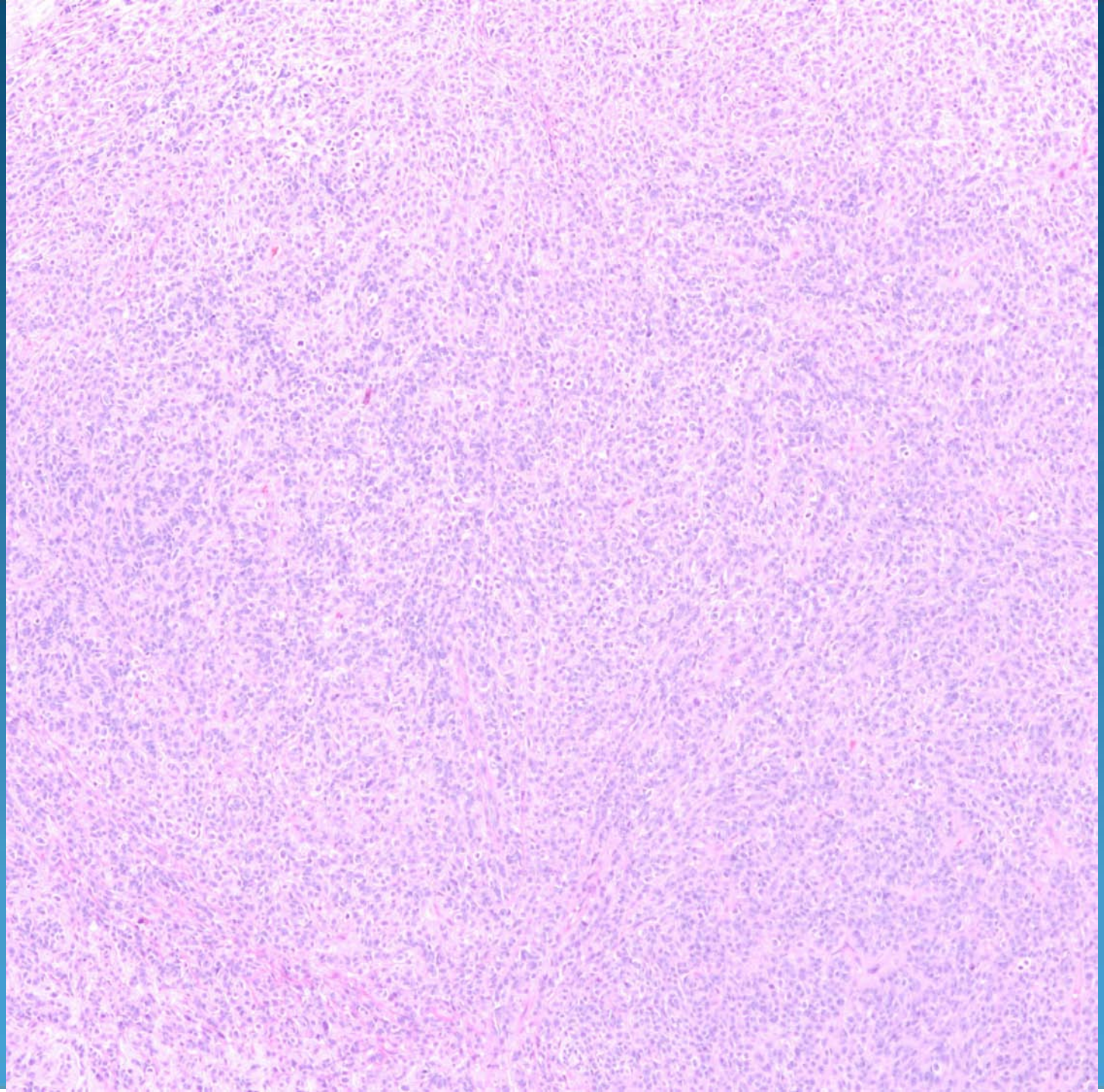

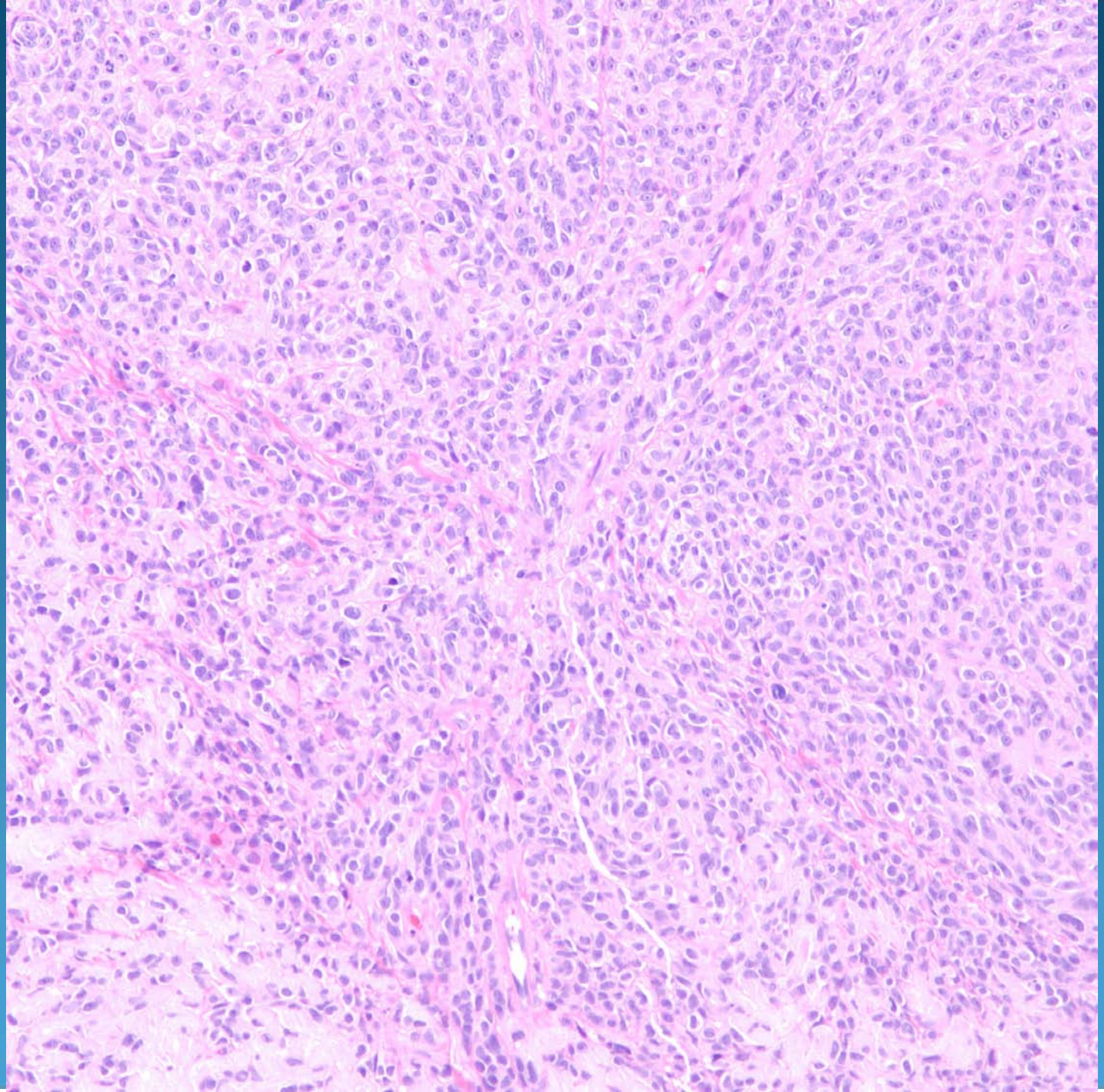

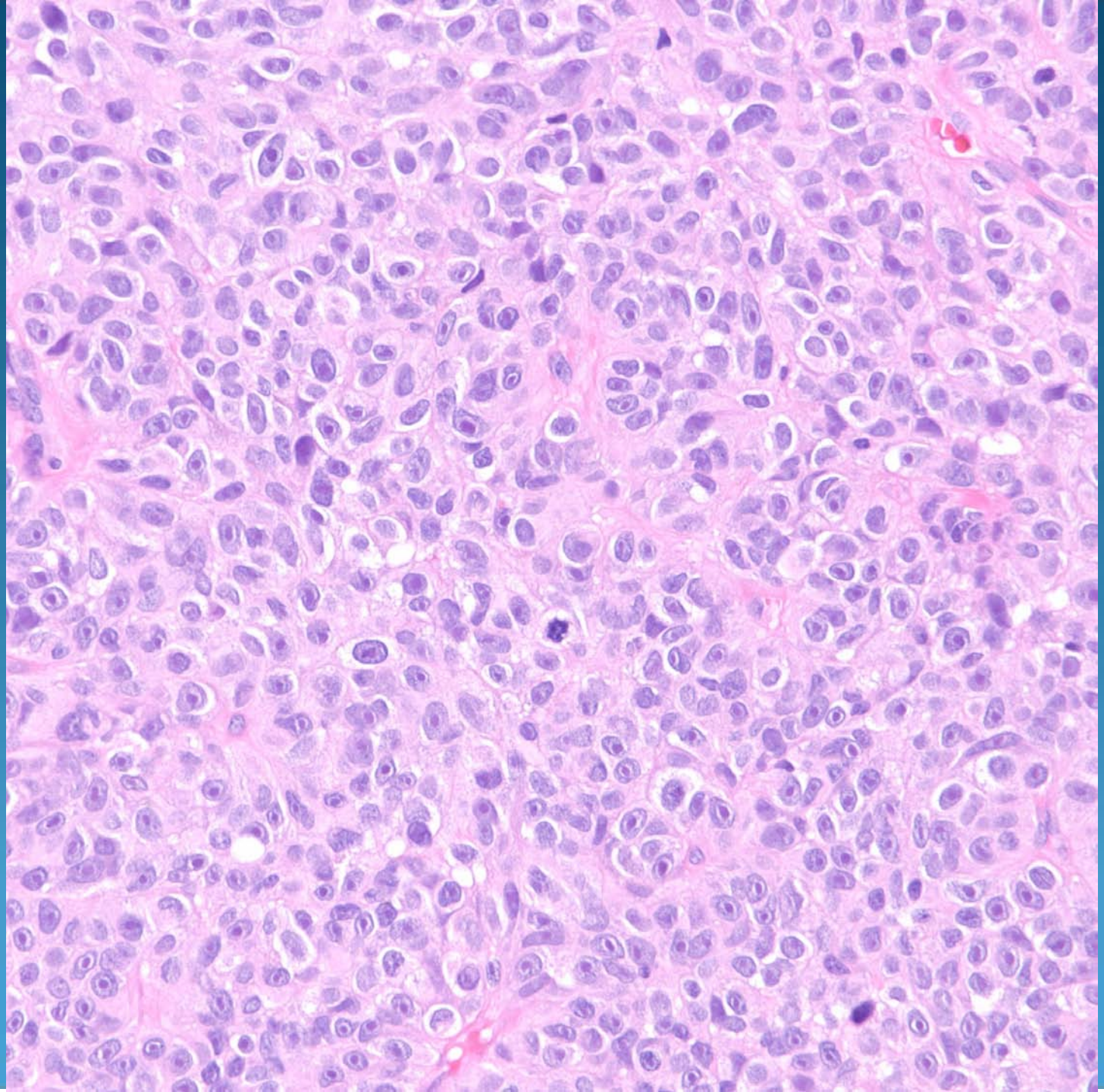

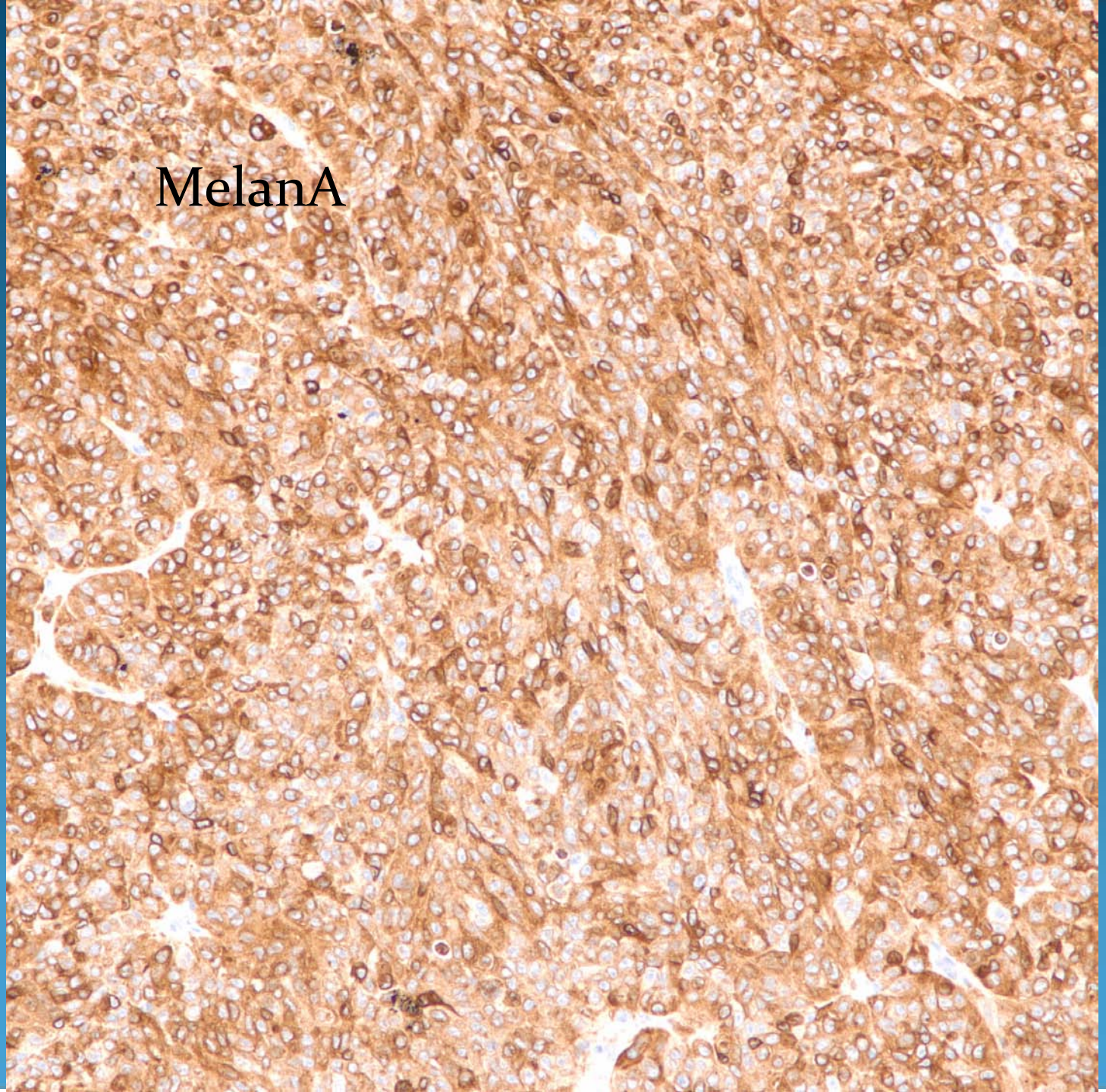
MelanA

Amelanotic Malignant Melanoma

Pearls

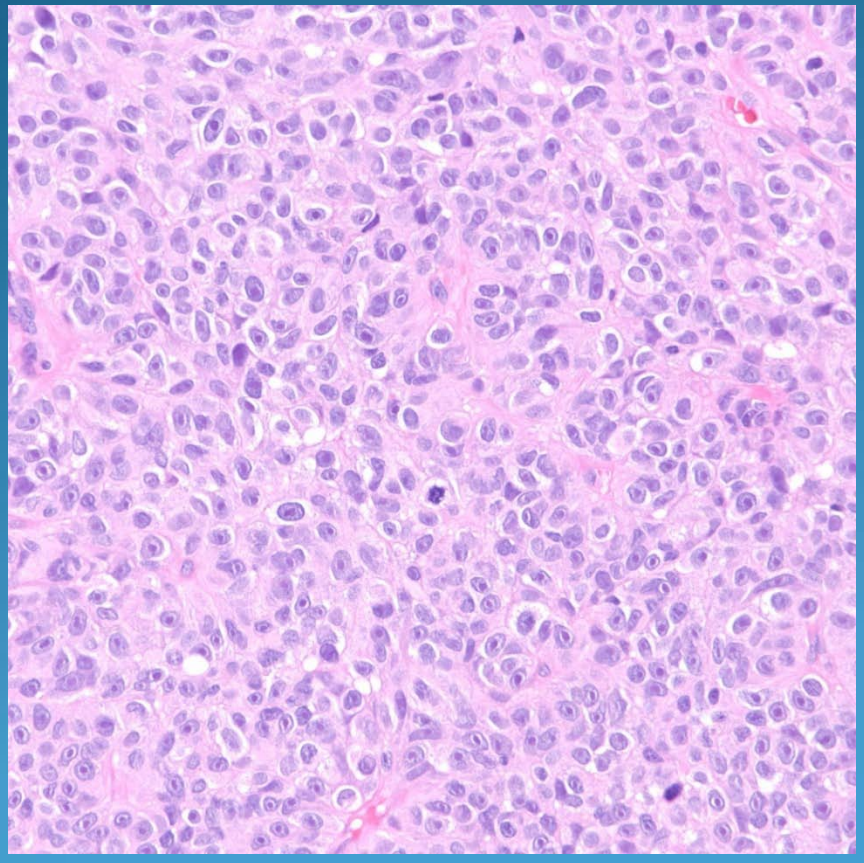

- Pleomorphic cellular tumor
- Look for epidermal junctional attachment
- Rule out lymphovascular invasion
- Confirm with IHC: S100 and MelanA+